

CORRESPONDENCE



Pregnancy after Transplantation of Cryopreserved Ovarian Tissue in a Patient with Ovarian Failure after Chemotherapy

TO THE EDITOR: Premenopausal women who undergo high-dose chemotherapy have a very high risk of ovarian failure.¹ Cryopreservation of ovarian tissue with subsequent autotransplantation has effectively preserved fertility in an animal model,² but its efficacy in humans has been uncertain. Eggs that were aspirated from cryopreserved ovarian tissue transplanted in heterotopic sites did not result in a pregnancy.³ A live birth was reported after transplantation of cryopreserved ovarian tissue in a woman who had undergone treatment for Hodgkin's disease; however, since the woman had ovulated before transplantation, it is uncertain whether the egg came from the native ovary or the transplanted ovary.⁴ A recent report described a live birth after transplantation of fresh ovarian tissue from a fertile woman to her sterile monozygotic twin, but this approach does not involve preservation of fertility and hence is not applicable to women facing sterilizing chemotherapy.⁵

We describe a live birth after *in vitro* fertilization following the transplantation of thawed cryopreserved ovarian cortical tissue into the ovaries of a 28-year-old woman who had ovarian failure after high-dose chemotherapy for non-Hodgkin's lymphoma. Ovarian tissue (containing many primordial follicles) was harvested after administration of a second-line conventional chemotherapy regimen, before treatment with high-dose chemotherapy (Fig. 1A). The patient's menses ceased after the high-dose chemotherapy. During the ensuing 24 months, the amenorrhea persisted, and laboratory testing consistently revealed high levels of follicle-stimulating hormone and luteinizing hormone (40 to 104 IU per liter) and undetectable levels of antimüllerian hormone and inhibin B — findings consistent with ovarian failure (Fig. 1B).

At 24 months, the patient remained free of disease and requested autotransplantation of the ovarian tissue in an attempt to restore fertility. After approval from the institutional review board and the patient's written informed consent had been obtained, a laparotomy was performed; strips of thawed ovarian tissue were transplanted to the left ovary, and small fragments were injected into the right ovary (Fig. 2). Eight months after transplantation, the patient spontaneously menstruated. Basal levels of antimüllerian hormone (which previously was undetectable) were found to be high, a finding consistent with the presence of active, early-stage, growing follicles.⁶ This change was followed by a rise in inhibin B levels to the levels reported in ovulatory women (Fig. 1B). Ultrasonography revealed a preovulatory follicle in the left ovary. The time from transplantation to recovery was compatible with the time needed for the growth and maturation of primordial follicles.⁷

Nine months after transplantation, the patient had a second spontaneous menstrual period. The level of follicle-stimulating hormone was 7.9 IU per liter, the level of luteinizing hormone 6.8 IU per liter, the level of estradiol 118 pg per milliliter, and the level of progesterone 0.5 ng per milliliter. A decision was made to perform *in vitro* fertilization. After a modified natural cycle,⁸ a single mature egg with a large cumulus was retrieved. The egg was fertilized *in vitro* with sperm from the patient's husband, and two days later, a four-cell embryo was transferred to the uterus. Serum testing for human chorionic gonadotropin was positive 12 days after the embryo transfer. Repeated ultrasonography during the pregnancy showed normal fetal growth and development. At 38 weeks 5 days of gestation, a healthy-appearing female infant weighing 3000 g

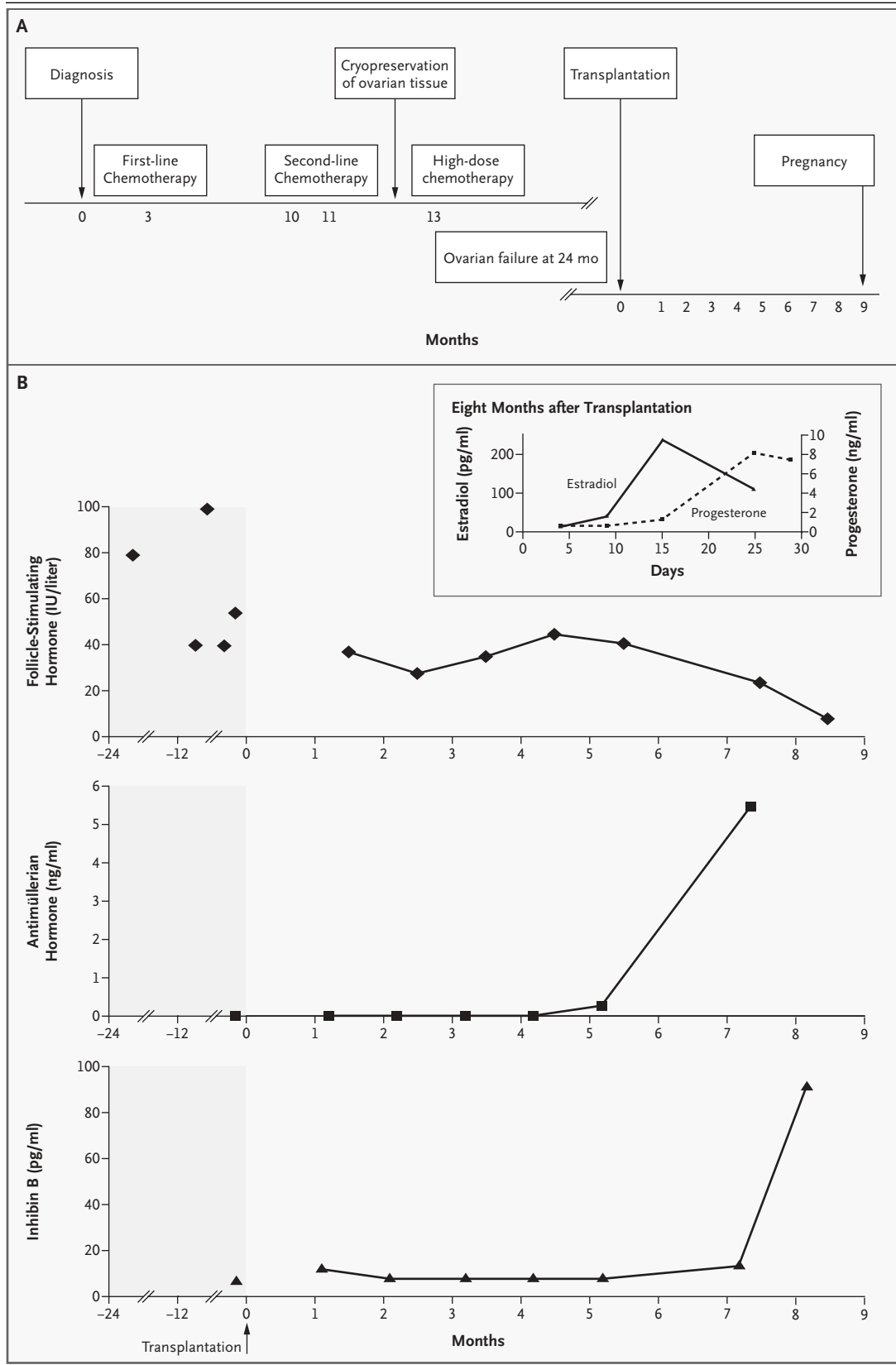


Figure 1 (facing page). Time Line of Treatment (Panel A) and Hormone Levels (Panel B).

After non-Hodgkin's lymphoma was diagnosed, a first-line chemotherapy regimen (etoposide, doxorubicin, cyclophosphamide, vincristine, bleomycin, and corticosteroids [VACOP-B]) was administered (Panel A), but a relapse occurred six months later; during that period the patient had monthly menstrual cycles. A second-line regimen (mesna, ifosfamide, mitoxantrone, etoposide, cytarabine, cisplatin, and corticosteroids [MINE-ESHAP]) was administered, followed by high-dose chemotherapy (carmustine, 300 mg per square meter of body-surface area; etoposide, 1600 mg per square meter; cytarabine, 1600 mg square meter; and melphalan 140 mg per square meter [BEAM]) with autologous stem-cell support. Ovarian tissue was harvested for cryopreservation before high-dose chemotherapy. Transplantation of thawed cryopreserved ovarian tissue was performed after 24 months of persistent ovarian failure. During the ninth month after transplantation, in vitro fertilization resulted in a pregnancy. Panel B shows basal blood levels of follicle-stimulating hormone, antimüllerian hormone, and inhibin B before and after transplantation. Six months after transplantation, the levels of follicle-stimulating hormone began to decrease gradually; normal levels were attained in the ninth month. The levels of antimüllerian hormone (based on three to five measurements every cycle) were undetectable until the sixth month after transplantation. High levels of antimüllerian hormone were measured during the eighth month after transplantation — a finding compatible with good ovarian reserve. Basal levels of inhibin B were undetectable after transplantation but became high during the ninth month. The levels of follicle-stimulating hormone were measured by a chemiluminescent immunometric method (Immulite 2000, Diagnostic Products); inhibin B levels were measured with the use of two-site enzyme-linked immunosorbent assays (Serotec); and levels of antimüllerian hormone were measured with the use of an ultrasensitive two-site enzyme-linked immunosorbent assay (Diagnostic Systems Laboratories). The inset shows hormone secretion during the eighth month after transplantation. Spontaneous menstruation was followed by a rise in estradiol levels, and the rise in progesterone levels after the 15th cycle day indicated luteinization.

was delivered by cesarean section. The Apgar scores were 9 at one minute and 10 at five minutes.

Transplantation of ovarian tissue is associated with a theoretical risk of grafting malignant cells. Tissue was harvested in this patient after therapy, with no evidence of disease, and conventional histologic analyses showed no cancer cells.

Although we cannot rule out the possibility that

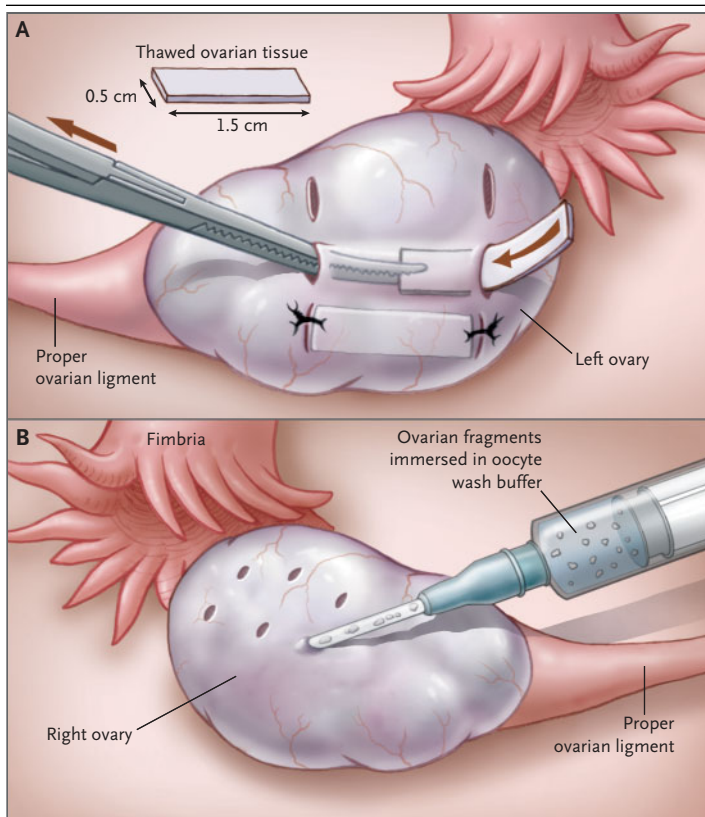


Figure 2. Surgical Technique.

Three pairs of 5-mm transverse incisions were made in the left ovary through the tunica albuginea (Panel A). With blunt dissection, cavities were formed beneath the cortex for each of the three strips. Each piece of thawed ovarian tissue (1.5 by 0.5 cm in area and 0.1 to 0.2 cm in thickness) was gently placed in a cavity, and the incisions were closed with 4/0 Vicryl sutures. In the smaller, right ovary, tiny ovarian fragments immersed in oocyte wash buffer were injected beneath the cortex (Panel B). Only the ovarian strips placed in the left ovary resumed function.

the egg was derived from the native ovary, we consider this possibility very unlikely, given the consistent evidence of ovarian failure after high-dose chemotherapy and the timing of restoration of ovarian function after transplantation. The hormone levels provided strong evidence of the success of transplantation, despite its being performed after initial chemotherapy, rather than of the activity of a few residual follicles. Our results indicate that fertility preservation with cryopreservation and orthotopic transplantation of ovarian tissue can be successfully performed in humans.

CORRESPONDENCE

Dror Meiorow, M.D.

Jacob Levron, M.D.

Chaim Sheba Medical Center
Tel Hashomer, Israel
meiorow@post.tau.ac.il

Talia Eldar-Geva, M.D., Ph.D.

Shaare-Zedek Medical Center
Jerusalem, Israel

Izhar Hardan, M.D.

Eduard Fridman, M.D.

Yaron Zalel, M.D.

Eyal Schiff, M.D.

Jehoshua Dor, M.D.

Chaim Sheba Medical Center
Tel Hashomer, Israel

1. Meiorow D, Nugent D. The effects of radiotherapy and chemotherapy on female reproduction. *Hum Reprod Update* 2001;7:535-43.

2. Gosden RG, Baird DT, Wade JC, Webb R. Restoration of fertility to oophorectomized sheep by ovarian autografts stored at -196°C . *Hum Reprod* 1994;9:597-603.

3. Donnez J, Dolmans MM, Demylle D, et al. Livebirth after orthotopic transplantation of cryopreserved ovarian tissue. *Lancet* 2004;364:1405-10. [Erratum, *Lancet* 2004;364:2020.]

4. Oktay K, Buyuk E, Veeck L, et al. Embryo development after heterotopic transplantation of cryopreserved ovarian tissue. *Lancet* 2004;363:837-40.

5. Silber SJ, Lenahan KM, Levine DJ, et al. Ovarian transplantation between monozygotic twins discordant for premature ovarian failure. *N Engl J Med* 2005;353:xxx-xx.

6. Fanchin R, Schonauer LM, Righini C, Guibourdenche J, Frydman R, Taieb J. Serum anti-Mullerian hormone is more strongly related to ovarian follicular status than serum inhibin B, estradiol, FSH and LH on day 3. *Hum Reprod* 2003;18:323-7.

7. Gougeon A. Regulation of ovarian follicular development in primates: facts and hypotheses. *Endocr Revs* 1996;17:121-55.

8. Elizur SE, Aslan D, Shulman A, Weisz B, Bider D, Dor J. Modified natural cycle using GnRH antagonist can be an optional treatment in poor responders undergoing IVE. *J Assist Reprod Genetics* 2005;22:75-9.

Correspondence Copyright © 2005 Massachusetts Medical Society.